

## Miniscrews: Clinical Application of Orthodontic.

Abu-Hussein Muhamad<sup>1\*</sup>, and Watted Nezar<sup>2</sup>.

<sup>1</sup>123 Argus Street, 10441 Athens, Greece.

<sup>2</sup>Arab American University, School of Dentistry, Department of Orthodontics, Jenin, Palestine.

### Review Article

Received: 29/05/2014

Revised : 13/06/2014

Accepted: 23/06/2014

#### \*For Correspondence

123 Argus Street, 10441  
Athens, Greece.

**Keywords:** Miniscrews, Mini-  
implant, Orthodontics,  
Anchorage.

#### ABSTRACT

The incorporation of miniscrews into orthodontic treatment planning has allowed for predictable anchorage control and has increased the ability to correct severe skeletal and dental discrepancies. Various miniscrews systems are now available for clinical use and abundant reports and studies are being published, dealing with different aspects of their applications (biology, surgical procedures, placement sites, complications, success rate). The aim of this article is to review the actual considerations regarding their mechanical properties, surgical considerations, risks and complications as well as their success rate and failure reasons.

#### INTRODUCTION

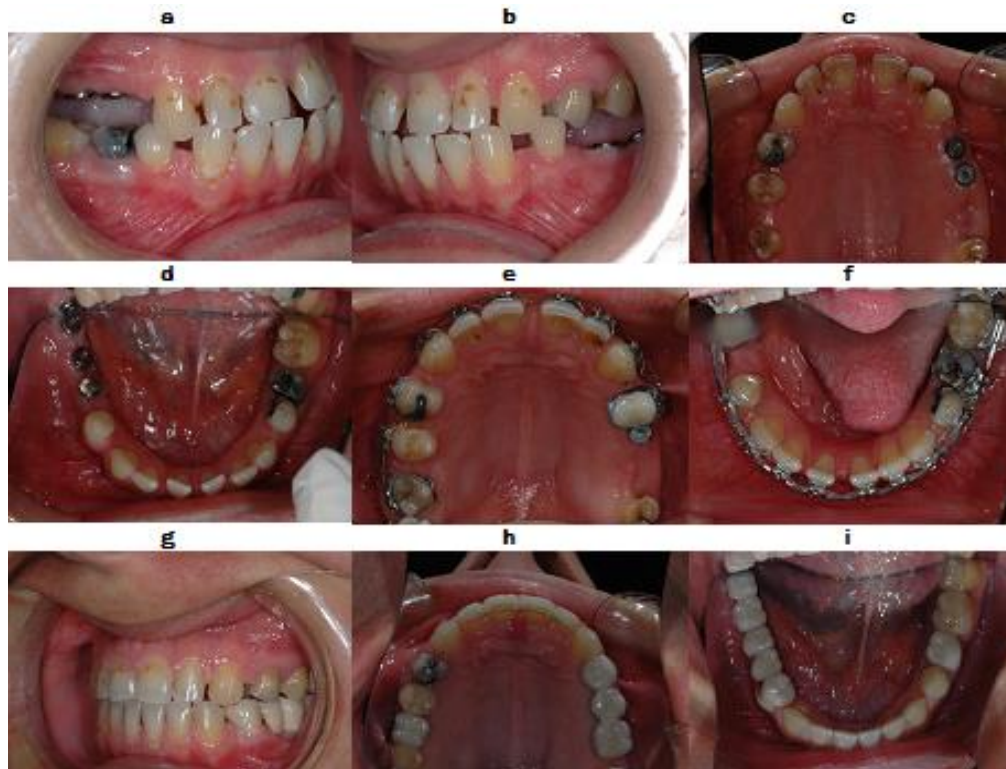The concept of skeletal anchorage is not new. Basal bone anchorage was suggested more than 60 years ago as an alternative to increasing the number of teeth to achieve conventional anchorage. Because of the limitations of headgear, clinicians sought other means of anchorage [1]. For example, orthopedists have used stainless steel bone screws for leg lengthening since before 1905. In 1945, research into the concept of using a pin or screw attachment to the ramus was initiated not only for moving teeth, but also for "exerting a pull on the mandible" [2].

One study involved placing Vitallium screws (Dentsply) in dogs. Using basal bone for anchorage, tooth movement was successful; however, it was found that an effective force could be maintained for no longer than 31 days [1,3]. The loss of all screws was attributed to infection from communication between the Vitallium screw and the oral cavity. Nonetheless, the authors concluded that "anchorage may be obtained for orthodontic movement in the future" [3].

Since 1969, when Branemark et al [5] introduced dental implants for tooth replacement and prosthetic rehabilitation, osseointegration has remained the singular goal. In the last 25 years, dental implants have been used successfully in combined management of orthodontic restorative patients, particularly in partially edentulous adults (FIG. 01a-i). Osseointegrated dental implants are used for orthodontic anchorage and then later serve as abutments for tooth replacement. This type of anchorage is very effective in treating patients with hypodontia, congenitally missing teeth, or periodontal disease, who lack sufficient teeth for conventional anchorage. Additionally, implants have been used for presurgical tooth movement, space opening/closing, and generally as a means to achieve better functional, biologic, and esthetic results in multidisciplinary treatment [3,4].

In 1978, Sherman [3] placed six vitreous dental implants into the extraction sites of mandibular third premolars in dogs and loaded them with orthodontic forces. Only two of the six implants were considered successful. Later on, Roberts and co-workers [4] investigated the osseous adaptation of rigid endosseous implants to continuous loading: titanium implants with an acid-etched surface were screwed into the femur of rabbits and were found to be useful as a source of firm osseous anchorage for orthodontics and dentofacial orthopaedics. They concluded that endosseous implants could be used as a firm osseous anchorage for orthodontics and dentofacial orthopaedics [1,4,5].

Figure 01 a-i: Osseointegrated dental implants are used for orthodontic anchorage and then later serve as abutments for tooth replacement



Orthodontic miniscrew implants have been designed to circumvent the limitations posed by restorative dental implants. These smaller bone screws are significantly less expensive, are easily placed and removed, and can be placed in almost any intra-oral region, including between the roots of the teeth. Some basic questions remain, however, concerning the limitations of miniscrews. Specifically, what is the maximum amount of lateral or shear force that can be applied to these miniscrews before they fail? How does a force that is applied immediately after the miniscrew is placed affect the maximum holding power of the implant? To what extent does the total length literature. of screw engaged in bone affect the maximum shear force the implant can withstand? These are questions ? [3,5,6].

For orthodontic purposes, however, standard implants of 3.25 to 7.0 mm in diameter were less than ideal. They required multiple-stage surgical procedures and a waiting period of 4 to 6 months for osseointegration before orthodontic loading could be activated. Lack of adequate bone to place the large-diameter dental implants restricted their use in some patients. In others, anatomic limitations (soft tissue, sinus, nerves, unerupted teeth in children, etc) were problems. Another disadvantage of osseointegrated implants involved the need to place them in edentulous areas, retromolar regions, along the palatine suture, or pterygoid areas.6-8 Finally, dental implant surgical protocols were invasive, expensive, uncomfortable for patients, and lengthy, and they excluded children under the age of 16 years [6].

In preparation for implant placement, good orthodontic records (panoramic, periapical, and cephalometric films, casts, etc) are required along with clinical findings and a definitive orthodontic treatment plan to determine the optimal position for implant placement. Site selection is critical and requires careful consideration of the hard and soft tissues, accessibility, patient comfort, and biomechanical needs. The actual implant placement is atraumatic, nonpainful, and requires minimal anesthesia [6,7].

All types of skeletal anchorage (including miniscrews) are, by definition, implants. It is important, however, to differentiate miniscrews from typical dental implants [1,3,5].

More than 30 different terms for skeletal temporary anchorage screws are in use in the international literature. The most common of these are mini-implant, mini-pin, miniscrew, or TAD (temporary anchorage device) ( FIG. 2). The term "miniscrew" appears to provide the most accurate (and most palatable) description of these "miniature screws," especially when discussing their use with

prospective patients . There are also more than 30 manufacturers of miniscrew systems , with the number of different screws offered per system ranging from two to 154. It can be an overwhelming and perplexing process to sort through all of these options and select those devices that are needed for daily practice. The following is an overview of the most important decision-making criteria for choosing a miniscrew system [1,3,5,6].

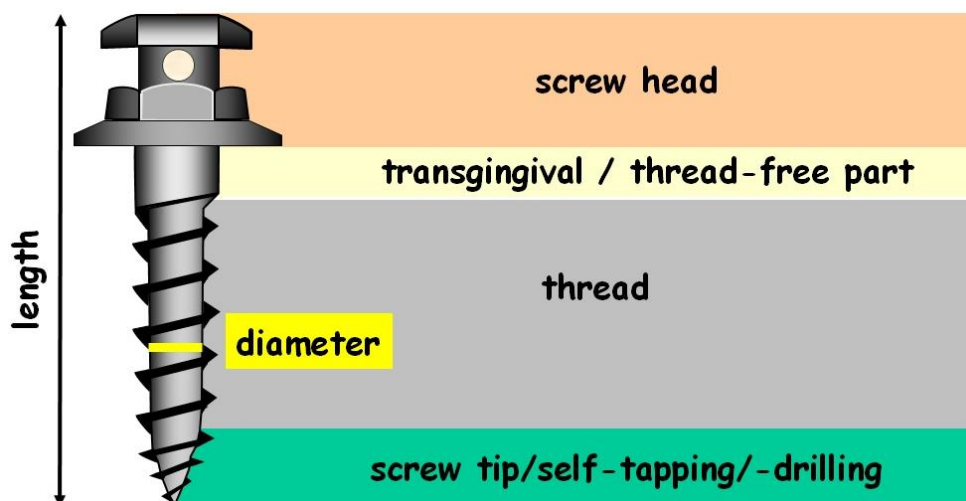
Figures 02: Types of Miniscrews



The stability of a miniscrew in the bone depends primarily on its diameter, and not on its length. The diameter of available miniscrews varies between 1.2 mm and 2.3 mm. In this case, “diameter” is the outside diameter of the threads. For safe and secure primary mechanical stabilization, a minimum amount of bone is required around the shank of the miniscrew . Although there is no definitive answer as to the amount of bone required, it appears that from between 0.5 mm to 2 mm is necessary for stabilization to reduce premature loss. The amount of bone between the roots of teeth, therefore, defines the maximum diameter of screw that can be used in a particular site. In short, the total distance between roots should be at least 1 mm greater than the diameter of the chosen miniscrew to provide adequate bone support [5,7,8].

The length of the various miniscrews on the market ranges from 5 mm to 14 mm. Typically, the length of the miniscrew refers only to the shaft or shank (the threaded section) (FIG. 03). As with the diameter, the selection of the length of a miniscrew is dependent upon the amount of bone available. Depending on the region, the total thickness of the alveolus is between 4 mm and 16 mm [5,7,8,9].

Figure 03: Orthodontic Miniscrew, Description



The length of a screw, however, is of secondary importance when it comes to secure anchorage—the diameter is much more critical. Various investigations have shown that the thickness of the cortical plate plays the most important role in miniscrew stability. For example, FEM analyses have demonstrated that the typical orthodontic load is applied only in the region of the cortical bone [7,9,10].

When selecting the length of a miniscrew, the depth of the gingiva must also be considered. The average depth of the gingiva is about 1.25 mm except in a few locations such as the retromolar region. The ratio between the length of the head (the part of the miniscrew outside the bone) and the length of the threaded shaft (the part of the screw inside the bone) should be at least 1:1. Consequently, Poggio et al recommended miniscrews lengths of 6 mm to 8 mm, and Costa suggested that miniscrews should be from 6 mm to 10 mm. On the basis of these investigations, it would appear that longer screws are unnecessary except in unusual circumstances. This has also been confirmed by numerous, anecdotal clinical experiences [8,10,11,12].

Color-coding of miniscrews for different lengths or diameters helps to facilitate the selection process. This color-coding is accomplished by an anodized surface coating. This oxide layer also appears to enhance retention of the miniscrew [11,12].

Some suppliers have a special head variation for every potential orthodontic application including:

- Hook Tops;
- Ball-Shaped Heads;
- Eyelets;
- Simple Slots;
- Cross-Shaped Slots; and
- Universal Heads.

The screw head must be very small and compact (low profile) to ensure that the patient experiences minimal discomfort and tissue irritation. On the other hand, the head must also be large enough so that the coupling elements (such as coil springs, wire segments, auxiliaries, and elastic chains) can be easily and securely fastened [13,14].

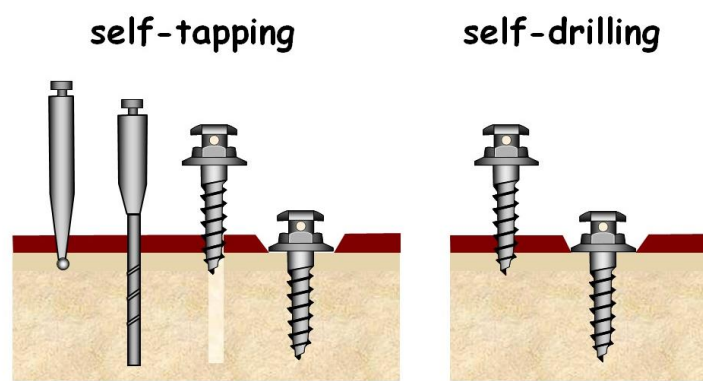
## CLINICAL APPLICATIONS

Clinicians must observe basic surgical techniques to prevent infection. Instruments and materials such as handpieces, hand screwdrivers, bone twist drills, and titanium mini-implants should be sterilized before surgery.

After disinfection of the placement site, infiltration anesthesia should be injected into a movable membrane.[15].

The surgical incision depends on the particular situation, as mucosal tissue can be caught in the bone twist drill. A pilot hole should be drilled before placement of a selftapping type screw. A self-drilling screw can be inserted into the bone by using a hand screwdriver, without a pilot hole (FIG. 04).

Figure 04: Screw selection

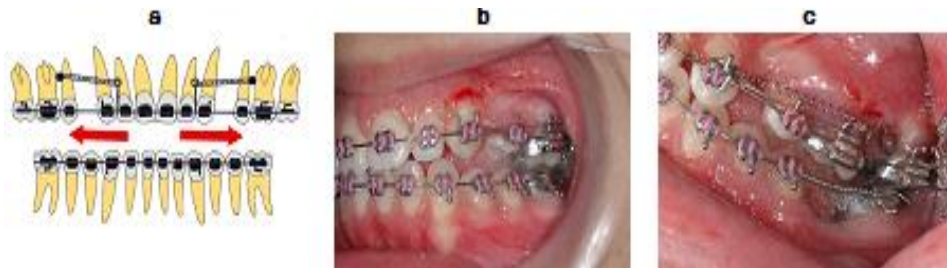

Miniscrews might be used in different steps of orthodontic treatment and in different dental and occlusal situations. Although their use cannot be theoretically limited, typical applications include the following:

### Anchorage control in space closure

Whether closing space is present from extracted or missing teeth or created as a result of molar distalization, the use of miniscrew anchorage provides a good control (FIG. 05a-c).

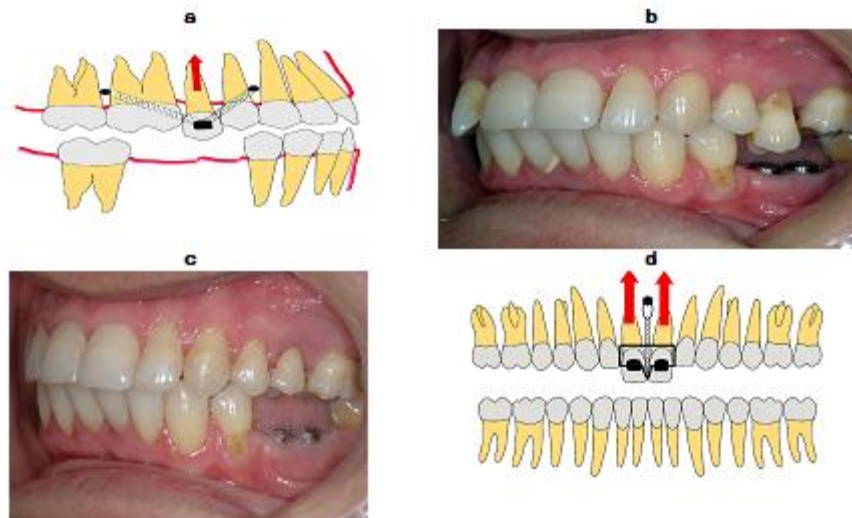
Figure 05a-c: Anchorage control in space closure



### Intrusion of over-erupted teeth

In the past, intrusion of such teeth was virtually impossible. The use of miniscrew anchorage allows troublefree intrusion of these problematic teeth (FIG. 06a-d).

Figure 06a-d: Intrusion of over-erupted teeth



### Traction of impacted teeth

In many instances, the precarious position of an impacted teeth, especially canines, can limit the ability to safely and effectively bring them on dental arch. Miniscrew anchorage allows force vectors that are otherwise hardly attainable (FIG. 07).

### Uprighting of mesially tipped molars (FIG. 08a, b).

### Correction of canted occlusal planes:

These cases have conventionally been accepted, ignored, or referred for correction with orthognathic surgery. Miniscrew anchorage can now be effectively used to correct asymmetries and canting of occlusal plane (FIG. 09).

Figure 07: Traction of impacted teeth

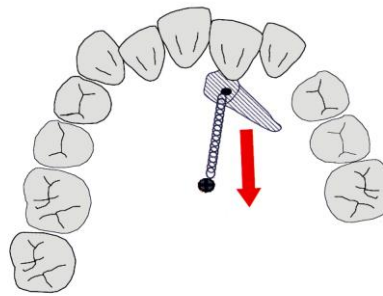


Figure 08a, b: Uprighting of mesially tipped molars

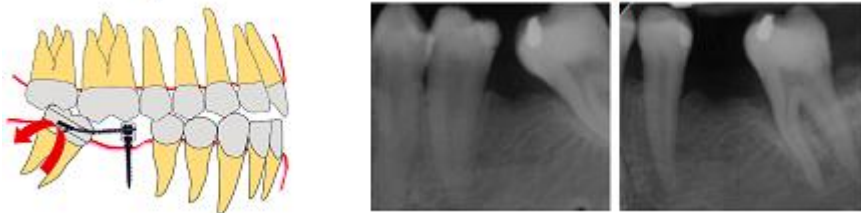
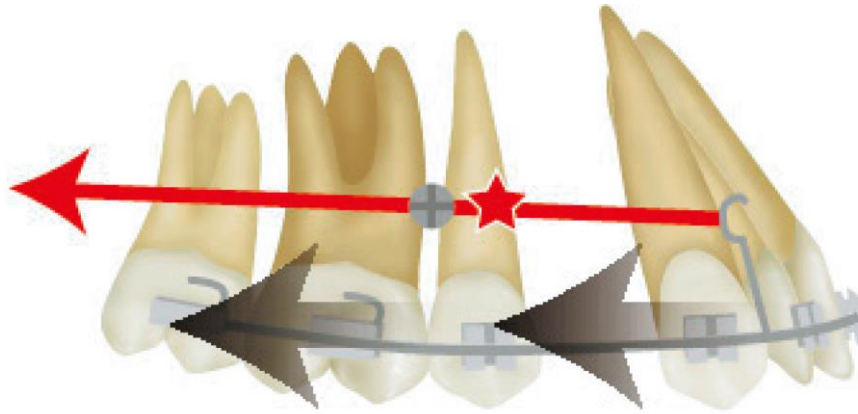


Figure 09: Correction of canted occlusal plane

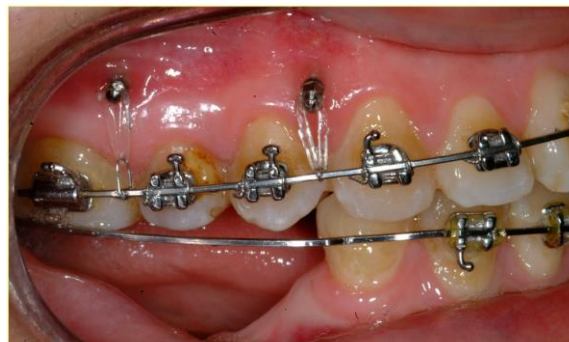
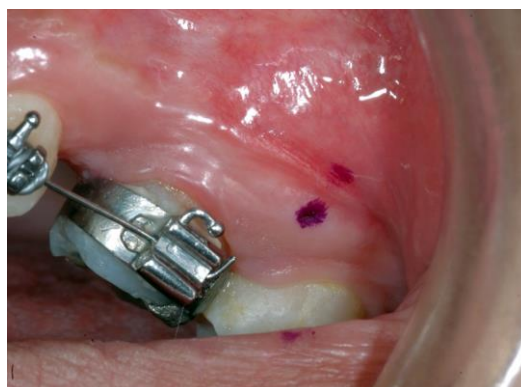
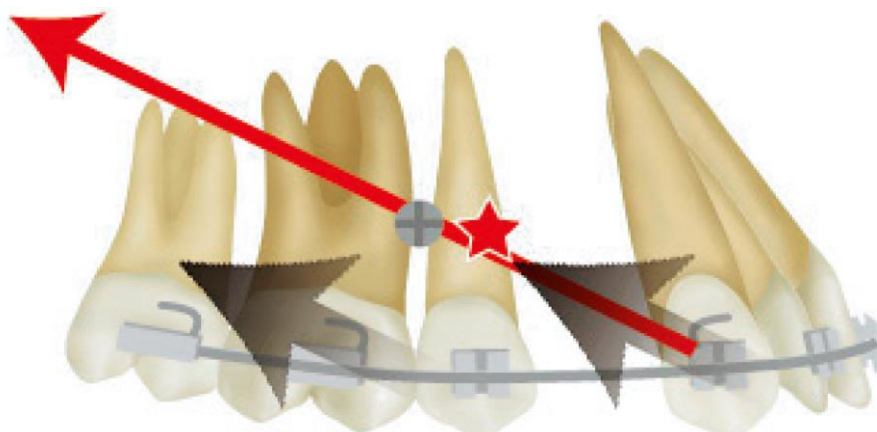
Figure 10: surgical procedure





**Table 1: Traction force and tooth movement. : Center of resistance (CR) of the dental arch. Red arrow: orthodontic traction force; Black arrows: direction of tooth movement. Parallel translation in the posterior direction is seen when the force vector is directed through the CR and remains parallel to the occlusal plane.**

Mini-implants are frequently placed in upper buccal alveolar bone between the second bicuspid and first molar in bicuspid extraction cases. Sung et al. simulated en-masse movement of the anterior segment using finite element analysis [16,17]. They hypothesized the center of resistance (CR) of the anterior segment and measured distortion of the archwire and tipping movement of the anterior teeth. However, this simulation calculated initial behavior immediately after force application [18]. Clinically, anterior and posterior teeth move and wire distortion would be cancelled over time when continuous, stiff archwire is used; the entire dental arch can be hypothesized as a massive structure. The present author then hypothesized the CR of the entire dental arch and attempted to simulate long-term behavior [19,20,21]. In bicuspid extraction, movement of the entire upper dental arch can be vertically controlled by alteration of the orthodontic force vector. If we posit a condition in which the anterior and posterior segments are rigidly fixed by inserting a stiff archwire into the bracket slots, the CR of the entire dental arch can be approximated around the root of the bicuspid, as shown in Table 1 to 3. When we intend to produce bodily movement of the anterior segment in patients with a mesiofacial pattern, the force vector should be parallel to the occlusal plane, as shown in Table 1. In patients with a distofacial pattern and excessive overbite, who require counterclockwise rotation of the mandible by depressing the entire maxillary dental arch, the force vector should be directed as shown in Table 2, so that it passes through the CR of the upper dental arch and the force is directed in a posterosuperior direction [22,23,24]. In a patient with a dolicofacial pattern and anterior open bite who is expected to depress the posterior teeth, it is effective to direct the force vector to pass inferior to the CR, as shown in Table 3 [23,25].

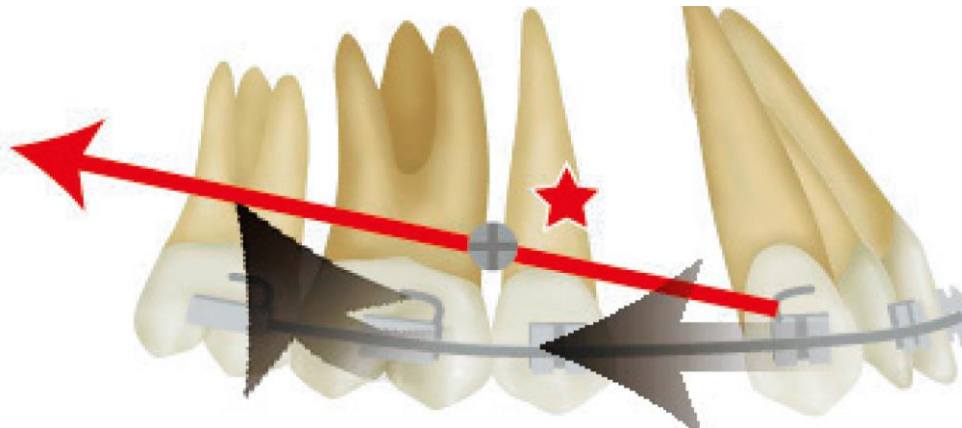


**Table 2: Parallel translation in the posterosuperior direction is seen when the force vector passes through the CR and is directed in a posterosuperior direction.**

### Anchorage in Orthodontics

The attainment and control of anchorage is fundamental to the successful practice of orthodontics and dentofacial orthopedics. According to Newton's well-known law of physics, action and reaction forces

are equal and opposite. In orthodontics, anchorage is used to describe resistance to reaction forces. Teeth are the usual source of anchorage and, in the typical orthodontic biomechanical situation, are pitted against one another to produce tooth movement. The teeth serving as the anchorage unit, by virtue of their number, position, size and number of roots, intend to offer resistance to movement so as to bring about the movement of the other teeth. A threshold value of force to initiate tooth movement has not



**Table 3: Depression of molars and distal movement of the anterior teeth is expected when the force vector is directed inferior to the CR.**

been identified, but appears to be very low. For example, tooth movement has been detected with as little as 4 gm of force. Considering this principle, it has been concluded that the practice of pitting more teeth with a larger root surface area against fewer teeth with less surface area in intra-arch mechanics may not be sufficient to prevent movement of anchor teeth. Therefore, in order to achieve increased anchorage control, a supplemental form of anchorage is often required. Traditionally, headgear and intermaxillary elastics have been used as forms of supplemental anchorage. While this form of supplemental mechanics may be effective in increasing anchorage, effectiveness depends upon the cooperation of the patient. Consequently, orthodontic anchorage control has historically been contingent on patient compliance. Due to the inconsistent nature of such compliance, orthodontists often note the unfavorable reciprocal movement of the intra-arch and inter-arch “anchor” teeth [3,8,12,17,18,22,23,24].

Orthodontists have recognized that stability of reactive anchorage units could be significantly increased if orthodontic anchorage could be provided by the skeletal bone itself, and in the 1940s began to conduct research on the subject. An early study by Bernier and Canby suggested that surgical titanium bone screws were inert and stable in bone. However, when Gainsforth and Higley attempted to use these screws as a source of orthodontic anchorage they were largely unsuccessfully [23,24,25].

### **Surgical Principles**

Surgical procedures for implantation of orthodontic miniimplants should be based on the following principles:

- Aseptic principle
- Atraumatic procedures
- Thorough preoperative examination and precise implant positioning
- Premedication for pain control
- Standardized procedures

Implants and instruments should be used under aseptic conditions. The driver tip is a female type, so blood and saliva can gather easily in the driver tip. The driver tip should be cleaned with a smooth brush and a neutral detergent as soon as possible following the conclusion of the procedure. Recycling of implants is prohibited by law and is also unfavorable from the viewpoint of stability, because the surfaces of implants are treated to increase biocompatibility; when in contact with body fluid, the surface changes continuously from the initial state. If there is even a small amount of surface contamination, the implant can be used after cleaning with an ultrasonic cleaner and autoclaving. However, repeated autoclaving has adverse effects on the biocompatibility of the surface [11,14,19,26].



To minimize surgical trauma, the surgical procedure should be performed with well-sharpened drills used at an appropriate speed under flowing saline coolant.<sup>2-5</sup> Appropriate cooling is needed to minimize damage from the heat generated during the insertion procedure. If insertional torque seems to increase abruptly, further attempts at insertion are undesirable because increased torque may be a sign that adjacent bone tissue is overstressed.

Thus, reverse rotation should be used to relieve stress on the adjacent bone. However, reverse rotation should never be used during insertion of the last 2.0 mm of an implant, because, otherwise, sufficient primary stability cannot be obtained [12,17,19,24,27].

The clinician should minimize unnecessary injuries to the anatomic structures by attaining a full awareness of the anatomy of the insertion area. More specifically, if the movement of teeth adjacent to an implant is planned, precise positioning of implants should be performed to ensure enough available space [18,19,20].

Pain control is very important to secure the patient's compliance. If the implant loosens, reinsertion is necessary, but the patient's experience with the first surgical placement of implants can greatly influence compliance with the second placement. For efficient pain control, premedication with analgesics 1 hour prior to or at surgery is recommended. In general, the prescription of systemic antibiotics, either preventatively before surgery or after surgery, is not necessary [19,20,21].

Although the new type of implant has a structure designed to minimize the influence of the operator's dexterity, the abilities and experience of the operator may still influence the success rate [25,27].

### Placement technique

Prior to placing the implant an intra-oral peri-apical or a panoramic radiograph of the region is essential to evaluate the inter-radicular space available; ideally, a minimum of 2 mm is required. Radiographic stents or guides such as twisted brass wire can be used as an aid to positioning. However, they only give a two-dimensional image, which indicates the correct implant insertion point, but offer no guidance to the drilling angle. This is best determined by direct vision as drilling proceeds [3,7,18,28,29].

A minimal amount of dental anaesthetic (about 0.3 ml) is given into the mucosa adjacent to the proposed implant placement site. The underlying bone has no innervation and profound anaesthesia of the adjacent teeth and periodontal ligaments (PDL) is contra-indicated. Any approximation of the drill or implant to the PDL will elicit pain, which will, in turn, alert the dentist to redirect the implant. This important feedback from the patient would not be possible with profound anaesthesia [29,30].

Wherever possible, the implant head should protrude through the attached gingiva and not the unattached alveolar mucosa. Insertion through alveolar mucosa tends to create more bleeding, is more traumatic and requires an initial incision to be made through the mucosa with a scalpel to prevent entanglement of the bur (FIG. 10a). For this reason and in order to take advantage of the increased apical inter-radicular space, the implant is placed at an angle of about 45° to the buccal/labial bone [13,17,29,30,31].

The implants come in various lengths (5–12 mm) and diameters (1.2–2 mm). It is the authors' experience that 1.5 mm is the optimal diameter to use. Thinner implants risk breakage and thicker implants make root contact more probable. In the mandible, where the bone is generally denser, a 6–8 mm length is optimal, while in the maxilla an 8–10 mm length is preferred.

To prevent the pilot twist drill slipping on the surface of the cortical bone, first pierce the cortical bone at right angles with a #2 round bur and then change the inclination of the drill to 45° to allow oblique drilling with the pilot drill. The pilot hole is drilled with a 1.2 mm twist drill, generally supplied with the implant kit, at 600 rpm to just short of the implant length. Self-drilling implants are available, although in our opinion the risk of going off course during placement is higher. While some clinicians prefer the self-drilling screw, we believe that the force required to place a self-drilling screw in bone reduces the tactile feel for the operator and may increase the risk of root contact. A gently drilled pilot hole, in our experience, offers better tactile feedback and placement precision. However, as yet there is no scientific evidence to support either technique [31,32].

The sterile implant is removed from its package with the handpiece driver attached to the handpiece. It is carried to the mouth without being touched by hand, placed into the pilot hole and driven,

with the handpiece at y??? r pm, three-quarters of the way and, if access permits, it driven to its full depth with a hand driver. Using a hand driver to do the final tightening of the implant offers better tactile feedback as to the tightness and stability of the implant (FIG. 10a-e). The implant needs only to be tightened to a torque value of 7–10 Ncm, which is achieved with mild finger tightening; achieving primary stability is essential. A post-operative radiograph should be taken to assure correct positioning of the implants [3,5,9,15,17,29,30].

## COMPLICATIONS

Accurate miniscrews placement should be performed with a thorough understanding of soft and hard tissue anatomy, surgical response, and healing to reduce pre and post-operative complications. Only few were reported in the literature:

- Infection of the insertion site if it is not kept absolutely clean; the infection is also associated with repeated drilling during placement.
- Inflammation around the implant. Screws placed in the attached gingiva without incisions are less likely to develop infection and inflammation. A mild swelling occurs with screws placed without a flap.
- Heat generation during drilling.
- Screw breakage because of an increased bone density or a decreased miniscrew diameter.
- Injury of anatomic structures such as nerves, blood vessels, roots and maxillary sinus. Some regions in both jaws do not allow a safe insertion for miniscrews like around sinus region or in the maxillary tuberosity basal bone in the mandible close to the dental nerve. In some situations, required width of inter-radicular bone is not enough and presence of permanent dental germs close to placement site will create surgical challenge to avoid teeth damage. Finally, the majority of authors agree that screws in the midpalatal area are not suitable for growing patients and have a low rate of success in adults. This is where a dental implant works better than screws.
- Pain and discomfort are among the unwanted outcomes of orthodontic MI use. When compared tooth extraction and fixed appliance insertion procedures, studies show less pain experience with MI than with any of them, and that patients tend to overestimate the pain anticipated in MI placement [31,32,33,34].

## CONCLUSIONS

The incorporation of dental implants into dental treatment plans has had a tremendous impact on virtually the entire field of dentistry. With the increased interest in the area of implantology has come a great deal of credible research exploring the use of dental implants. Indeed, evidence-based dentistry is the basis for sound clinical decision making and treatment planning modalities. Whereas the conventional use of dental implants has been studied for some time now, the use of implants and implantable devices as described in this article is relatively new by comparison. Therefore, the literature is limited in clinical trials and other more rigorous evaluation methods. At this time, the body of research associated with this subject is composed largely of case reports and a few small time limited trials in animals. There is no doubt that this area will continue to be explored and researched and will probably become an indispensable part of contemporary orthodontic therapy in the future. Purely as a matter of opinion, it seems that the extent to which the use of implants or implantable devices is accepted by the field of orthodontics on a broad basis will depend on a few specific factors. It seems that the devices themselves will continue to evolve but will probably move in a direction that supports the best combination of ease of placement (able to be placed by orthodontist), least invasive procedure, and best physical design properties to deliver optimum mechanical forces. Perhaps the use of dental implants will prove to be as useful to the field of orthodontics as it has been for other areas of dentistry.

## ACKNOWLEDGEMENTS

The author is very grateful to the clinicians who spent great deal of time filling in survey forms for this study.

## REFERENCES

1. Proffit WR. Contemporary orthodontics (3rd ed). St Louis: Mosby 2000.
2. Angle EH. Malocclusion of the Teeth and Fractures of the Maxillae, ed Philadelphia: S.S. White Dental, 1900:110

3. Ismail SFH, Johal AS. The role of implants in orthodontics. *J Orthod.* 2002;29:239-45.
4. Roberts WE, Marshall KJ, Mozsary PG. Rigid endosseous implant utilized as anchorage to protract molars and close atrophic extraction site. *Angle Orthod.* 1989;60:135-51.
5. Gelgor IE, Buyukyilmaz T, Karaman AI, Dolanmaz D, Kalayci A. Intraosseous screw-supported upper molar distalization. *Angle Orthod.* 2004;74:838-850.
6. Costa A, Raffaini M, Melsen B. Miniscrews as orthodontic anchorage: A preliminary report. *Int J Orthod Orthognath Surg.* 1998;13:201-09.
7. Deguchi T, Takano-Yamamoto T, Kanomi R, Hartsfield J K Jr, Roberts WE, Garetto LP. The use of small titanium screws for orthodontic anchorage. *J Dent Res.* 2003;82:377-381.
8. Baumgaertel S, Razavi MR, Hans MG. Mini-implant anchorage for the orthodontic practitioner. *Am J Orthod Dentofacial Orthop.* 2008;133:621-7.
9. Kulberg A, Nanda R. Principles of Biomechanics. In Ravindra Nanda editor: *Biomechanics and Esthetic strategies in Clinical orthodontics*, St. Louis, 2005, Elsevier-Saunders, pp 1-16
10. Kyung HM, Park HS, Bae SM, Sung JH, Kim IB. Development of orthodontic micro-implants for intraoral anchorage. *J Clin Orthod.* 2003;37:321-328
11. Wehrbein H, Glatzmaier J, Mundwiler U, Diedrich P. The Orthosystem: a new implant system for orthodontic anchorage in the palate. *J Orofac Orthop.* 1996;57:142-
12. Costa A, Raffaini M, Melsen B. Miniscrews as orthodontic anchorage: A preliminary report. *Int J Orthod Orthognath Surg.* 1998;13:201-09.
13. Creekmore TD, Eklund MK. The possibility of skeletal anchorage. *J Clin Orthod.* 1983;17:266-269.
14. Block M. Orthodontic and orthopedic anchorage using subperiosteal bone anchors. In: Higuchi KW (ed). *Orthodontic Applications of Osseointegrated Implants*. Chicago: Quintessence, 2000:110-116.
15. Kaku M, Kawai A, Koseki H, et al. Correction of severe open bite using miniscrew anchorage. *Australian Dental J.* 2009;54:374-380.
16. Ludwig B, Glasl B, Bowman SJ, Wilmes B, Kinzinger GS, Lisson JA. Anatomical guidelines for miniscrew insertion: Palatal sites. *J Clin Orthodontic.* 2011;45:433-441.
17. Topouzelis, N. and Tsaousoglou, P. Clinical factors correlated with the success rate of miniscrews in orthodontic treatment. *Int J Oral Sci.* 2012;4:38-44.
18. DeVincenzo JP. A new non-surgical approach for treatment of extreme dolichocephalic malocclusions. Part 1. Appliance design and mechanotherapy. *J Clin Orthodontics.* 2006;40:161-170.
19. Jamilian A, Showkatbakhsh R. Treatment of maxillary deficiency by miniscrew implants: A case report. *J Orthodontics.* 2010;37:56-61.
20. Cheng SJ, Tseng IY, Lee JJ, Kok SH. A prospective study of the risk factors associated with failure of mini-implants used for orthodontic anchorage. *Int J Oral Maxillofac Implants.* 2004;19:100-106.
21. Park HS, Bae SM, Kyung HM, Sung JH Simultaneous incisor retraction and distal molar movement with microimplant anchorage. *World J Orthod.* 2004;5(2):164-71.
22. Çifter M, Saraç M. Maxillary posterior intrusion mechanics with mini-implant anchorage evaluated with the finite element method. *Am J Orthod Dentofacial Orthop.* 2011;140(5):e23-41.
23. Maino BG, Mura P, Bednar J. Miniscrew implants: the spider screw anchorage system. *Semin Orthod.* 2005;11:40-6.
24. Türköz C, Ataç MS, Tuncer C, Balos Tuncer B, Kaan E. The effect of drill-free and drilling methods on the stability of mini-implants under early orthodontic loading in adolescent patients. *Eur J Orthod.* 2011;33(5):533-6.
25. Baxmann M, McDonald F, Bourauel C, Jäger A. Expectations, acceptance, and preferences regarding microimplant treatment in orthodontic patients: A randomized controlled trial. *Am J Orthod Dentofacial Orthop.* 2010;138(3):250.e1-250.e10.
26. Marquezan M, Souza MM, Araújo MT, Nojima LI, Nojima Mda C. Is miniscrew primary stability influenced by bone density? *Braz Oral Res.* 2011;25(5):427-32.
27. Chen CH, Chang CS, Hsieh CH, Tseng YC, Shen YS, Huang IY, Yang CF, Chen CM. The use of microimplants in orthodontic anchorage. *J Oral Maxillofac Surg.* 2006;64(8):1209-13.
28. Chen CM, Chang CS, Tseng YC, Hsu KR, Lee KT, Lee HE. The perception of pain following interdental microimplant treatment for skeletal anchorage: a retrospective study. *Odontology.* 2011;99(1):88-91.
29. Lee TC, McGrath CP, Wong RW, Rabie AB. Patients' perceptions regarding microimplant as anchorage in orthodontics. *Angle Orthod.* 2008;78(2):228-33.
30. Barros SE, Janson G, Chiqueto K, Garib DG, Janson M Effect of mini-implant diameter on fracture risk and self-drilling efficacy. *Am J Orthod Dentofacial Orthop.* 2011;140(4):e181-92.
31. Carano A, Melsen B. Implants in orthodontics. *Prog Orthod.* 2005;6:62-9.

32. Chapman JR, Harrington RM, Lee KM. Factors affecting pullout strength of cancellous bone screws. *J Biomech.* 1996;118:391-8.
33. Kuroda S, Sugawara Y, Degushi T, Kyung H-M, Takano- Yamamoto T. Clinical use of miniscrew implants as orthodontic anchorage: Success rates and postoperative discomfort. *Am J Orthod Dentofacial Orthop.* 2007;131:9-15.
34. Applications of orthodontic mini-implants. Lee JS, Kim JK, Park Y-C, Vanarsdall, Jr RL. Quintessence, 2007.