

TECPR2-related hereditary sensory and autonomic neuropathy in two siblings from Palestine

Reham Khalaf-Nazzal¹ | Imad Dweikat¹ | Nishanka Ubeyratna² |
James Fasham^{2,3}  | Maysa Alawneh^{4,5} | Joseph Leslie² | Mosab Maree⁴ |
Adam Gunning² | Deyala Z. Zayed⁵ | Nikol Voutsina² | Lucy McGavin^{6,7} |
Reem Sawafta⁵ | Martina Owens² | Wisam Baker⁸ | Peter Turnpenny³ |
Fida' Al-Hijawi⁹ | Emma L. Baple^{2,3}  | Andrew H. Crosby²  | Lettie E. Rawlins^{2,3} 

¹Faculty of Medicine, Arab American University of Palestine, Jenin, Palestine

²RILD Wellcome Wolfson Medical Research Centre, Royal Devon University Hospitals NHS Foundation Trust, University of Exeter Medical School, Exeter, UK

³Peninsula Clinical Genetics Service, Royal Devon & Exeter Hospital (Heavitree), Exeter, UK

⁴Department of Medicine, College of Medicine and Health Sciences, An-Najah National University, Nablus, Palestine

⁵Paediatric Department, An-Najah National University Hospital, Nablus, Palestine

⁶University Hospitals Plymouth NHS Trust, Plymouth, UK

⁷University of Plymouth, Plymouth, UK

⁸Paediatric Department, Dr. Khalil Suleiman Government Hospital, Jenin, Palestine

⁹Paediatric Community Outpatient Clinics, Palestinian Ministry of Health, Jenin, Palestine

Correspondence

Reham Khalaf-Nazzal, Faculty of Medicine,
Arab American University of Palestine, Jenin,
Palestine.

Email: reham.nazzal@aaup.edu

Lettie E. Rawlins, RILD Wellcome
Medical Research Centre, Royal Devon
University Hospitals NHS Foundation Trust,
University of Exeter Medical School, Exeter,
UK.

Email: l.rawlins@exeter.ac.uk

Funding information

Medical Research Foundation, Grant/Award
Number: MRF-145-0006-DG-BAPL-C0788;
European Union: Unity and Diversity in Nature
and Society Project, Grant/Award Number:
ENI/2019/412-148; Medical Research
Council, Grant/Award Numbers: MC-PC-
18047, MC_PC_15054; National Institute for
Health and Care Research

Abstract

Due to the majority of currently available genome data deriving from individuals of European ancestry, the clinical interpretation of genomic variants in individuals from diverse ethnic backgrounds remains a major diagnostic challenge. Here, we investigated the genetic cause of a complex neurodevelopmental phenotype in two Palestinian siblings. Whole exome sequencing identified a homozygous missense *TECPR2* variant (Chr14(GRCh38):g.102425085G>A; NM_014844.5:c.745G>A, p.(Gly249Arg)) absent in gnomAD, segregating appropriately with the inheritance pattern in the family. Variant assessment with *in silico* pathogenicity prediction and protein modeling tools alongside population database frequencies led to classification as a variant of uncertain significance. As pathogenic *TECPR2* variants are associated with hereditary sensory and autonomic neuropathy with intellectual disability, we reviewed previously published candidate *TECPR2* missense variants to clarify clinical outcomes and variant classification using current approved guidelines, classifying a number of published variants as of uncertain significance. This work highlights genomic healthcare inequalities and the challenges in interpreting rare genetic variants in populations underrepresented in genomic databases. It also improves understanding of the clinical and genetic spectrum of *TECPR2*-related neuropathy and contributes to addressing

This is an open access article under the terms of the [Creative Commons Attribution](https://creativecommons.org/licenses/by/4.0/) License, which permits use, distribution and reproduction in any medium, provided the original work is properly cited.

© 2024 The Authors. *American Journal of Medical Genetics Part A* published by Wiley Periodicals LLC.

genomic data disparity and inequalities of the genomic architecture in Palestinian populations.

KEYWORDS

autonomic neuropathy, autophagy, encephalopathy, Palestinian, *TECPR2*

1 | INTRODUCTION

Current genomic reference data are predominantly derived from populations of European ancestry (Popejoy et al., 2018; Sirugo et al., 2019). Despite the Middle East comprising approximately 6% of the world population only 0.2% (158/76,156) of genomes in gnomAD v3.1.2 derive from individuals with Arab ancestry (Karczewski et al., 2020). This striking genomic data disparity leads to challenges in interpreting the clinical relevance of rare genetic variants in families from under-represented populations, inhibiting diagnostic provision. Thus, while several initiatives are beginning to address this genomic data disparity a great deal more still needs to be done to enable transferability of findings and benefits (Darr et al., 2016).

Autosomal recessive pathogenic variants in the tectonin β -propeller repeat-containing protein 2 (*TECPR2*) gene have been described as the cause of hereditary sensory and autonomic neuropathy (HSAN) type IX, with developmental delay (OMIM #615031, previously hereditary spastic paraplegia [HSP] type 49). *TECPR2* encodes a highly conserved protein constrained to missense variation and predicted to contain seven N-terminal bladed β -propeller fold (WD40) repeat domains and six *TECPR*-repeats forming a double β -propeller motif within the C-terminus (Neuser et al., 2021). *TECPR2*-related clinical presentations include both neurodevelopmental and neurodegenerative features involving central and peripheral nervous systems, with core features of global developmental delay, moderate/severe intellectual disability, muscular hypotonia, dysarthria, abnormal gait, and behavioral abnormalities, with variable features of spasticity, hyporeflexia, and autonomic dysregulation leading to central apnea/hypopnea, temperature, and blood pressure dysregulation, abnormal gastrointestinal motility and dysphagia or gastroesophageal reflux with repeat pulmonary aspiration. Recurrent episodes of acute respiratory dysregulation and decompensation are frequently associated with mild concurrent illnesses, sometimes requiring noninvasive or ventilatory support and resulting in severe morbidity and early childhood mortality (Heimer et al., 2022; Neuser et al., 2021).

To date, 29 individuals from 25 families have been described with *TECPR2*-related HSAN with 22 *TECPR2* variants (12 truncating and 10 missense) (Guan et al., 2022; Neuser et al., 2021; Ramsey et al., 2022). Two founder pathogenic variants have been described in the Jewish Bukharian (NM_014844.5:c.3416del, p.(Leu1139Argfs*75)) (Oz-Levi et al., 2013) and Ashkenazi (NM_014844.5:c.1319del, p.(Leu440Argfs*19)) populations (Neuser et al., 2021). Here we report a novel homozygous missense Palestinian *TECPR2* gene variant associated with a severe neurodevelopmental disorder presenting with episodes of transient encephalopathy, liver dysfunction, and muscle

injury, expanding the knowledge of the genomic landscape of neurodevelopmental disorders within the Palestinian population, underrepresented in publicly available genomic databases.

2 | CASE REPORT

2.1 | Clinical findings

Here, we report two affected siblings (one male, IV:2; one female, IV:3) born to healthy consanguineous Palestinian parents (Figure 1a). Individual IV:2 was a 5-year-old male born at full term, following an uneventful pregnancy, with a birth weight of 3400 g (+0.1 SD), length 52 cm (+1.1 SD), and occipitofrontal circumference (OFC) 38 cm (+2.8 SD). Hypotonia and developmental delay were first noted at 9 months. He walked at 19 months and had 10 words by 22 months. At 2 years, he had been diagnosed with bilateral sensorineural hearing impairment, had moderate to severe intellectual disability, chronic constipation, strabismus, and behavioral features including hyperactivity, aggressive episodes, sleep disturbances, self-harm with facial picking/scratching, and head banging. At 3 years, he was admitted to intensive care requiring intubation and mechanical ventilation, after a 2-day history of viral gastroenteritis with fever, respiratory difficulties, reduced consciousness, dehydration, tonic-clonic seizures, and exacerbation of hypotonia. Investigations showed elevated inflammatory markers (erythrocyte sedimentation rate [ESR] 70 mm/h, C-reactive protein [CRP] 31), hyperglycemia (285 mg/L), elevated plasma sodium (148 mmol/L), and chloride (118 mEq/L), low potassium (2.8 mmol/L), and calcium (2.03 mmol/L) levels. Other findings included elevated aspartate aminotransferase (AST, 333 U/L), alanine aminotransferase (ALT, 101 U/L), creatine kinase (CK, 220 U/L), and creatine kinase myocardial band isoform (CK-MB, 162 U/L then 115.5 U/L) with acute renal impairment (serum creatinine, 1.69 mg/dL). Cerebrospinal fluid (CSF) analysis excluded meningitis and brain magnetic resonance imaging (MRI) excluded any acute intracranial pathology. Echocardiography and metabolic investigations, including plasma amino acids and urine organic acids, were unremarkable. The clinical condition improved over 16 days and he was discharged. Assessment at 5 years revealed unremarkable growth parameters (height 106 cm, -0.68 SD; OFC 51.5 cm, $+1.57$ SD), subtle craniofacial dysmorphism (short broad neck, malar widening, downslanting palpebral fissures, wide nasal bridge, pointed nasal tip, and low columella (Figure S1a–c). He had a wide-based gait, hypotonia, thin lower limbs with muscle atrophy, cold extremities, and brisk lower limb reflexes with bilateral upgoing plantar responses. MRI neuroimaging (Figure S1d,e) revealed

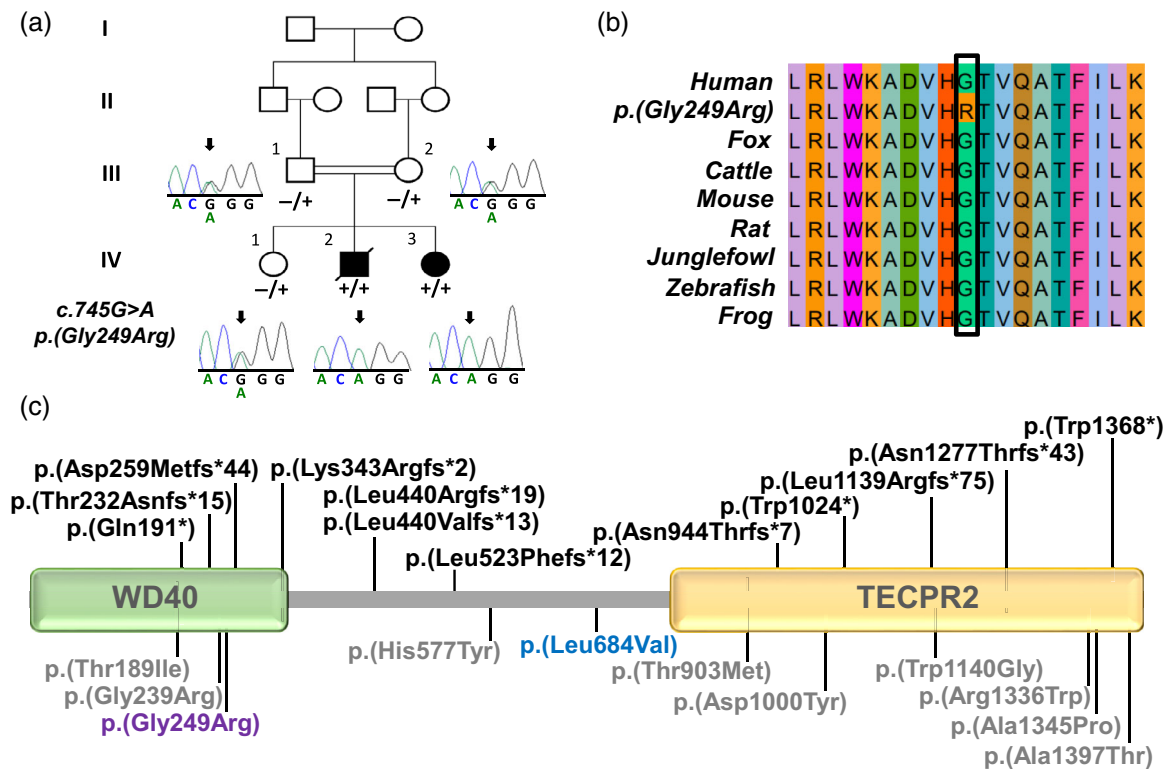


FIGURE 1 Homozygous *TECPR2* missense variant identified in a Palestinian family with *TECPR2*-hereditary sensory and autonomic neuropathy (*TECPR2*-HSAN). (a) Pedigree of the Palestinian family with two affected siblings (one male, deceased; one female) both homozygous for the *TECPR2* NM_014844.5:c.745G>A, p.(Gly249Arg) variant (“+”) with co-segregation confirmed in other family members (“-” indicates the wild-type allele), as shown by dideoxy sequence chromatograms. (b) Multiple species sequence alignment showing conservation of the polypeptide region encompassing the NM_014844.5:c.745G>A, p.(Gly249Arg) variant (black box). (c) Schematic diagram of the *TECPR2* protein with WD40 (yellow) and TECPR2 (green) functional domains architecture showing the location of previously identified pathogenic *TECPR2* variants (top, black), variants of uncertain significance (bottom, gray), benign variants (blue) and the novel NM_014844.5:c.745G>A, p.(Gly249Arg) variant reported here (purple).

thinning of the posterior body and splenium of the corpus callosum, dysmorphic straightened ventricles, and mild frontal volume loss. The child had a further episode of acute encephalopathy associated with fever and intercurrent illness at the age of 5.5 years and died shortly after admission with reduced Glasgow Coma Scale (GCS), rapidly progressive metabolic acidosis and multi-organ failure.

Individual IV:3 (Figure 1a) a 3-year-old female was born at full term after an uncomplicated pregnancy (birth weight, 3300 g, -0.1 SD, length 50 cm, $+0.5$ SD and OFC 35 cm, -0.67 SD). Kernicterus requiring exchange transfusion and poor feeding complicated the neonatal period. She had recurrent pneumonia requiring hospital admission and evaluation at 6 months revealed significant gastroesophageal-reflux disease causing aspiration, hypotonia, and severe sensorineural hearing loss detected on auditory brainstem responses. MRI neuroimaging (Figure S1i,j) showed diffuse thinning of the corpus callosum, with prominent cortical sulci and enlarged ventricles indicating marked reduction of cerebral volume. At 22 months, she was admitted to intensive care for 4 days, requiring immediate intubation and ventilation following an acute encephalopathic episode and respiratory tract infection. She presented with respiratory distress, generalized tonic-clonic seizures, fever (41°C), exacerbation of hypotonia, poor response

to painful stimuli, diminished pupillary reflexes, and upgoing plantar responses bilaterally. Investigations showed raised CRP (45 mg/dL), hypernatremic dehydration (sodium 161 mmol/L), impaired renal function (blood urea nitrogen 71 mg/dL, creatinine 1.8 mg/dL), hyperglycemia (350 mg/dL), hypocalcemia (1.5 mmol/L), pancytopenia, and elevated liver enzymes (ALT 154 U/L, AST 650 U/L). During hospitalization, a severe transient myopathy developed with progressive elevation of CK (up to 46,439 U/L), CK-MB (425 U/L), lactate dehydrogenase (LDH, 2339 U/L), and AST (650 U/L). Echocardiography and electromyography were unremarkable. Muscle power improved gradually, although severe hypotonia and ongoing weakness with poor swallow persisted requiring gastrostomy. At age 2 years, a further episode of acute encephalopathy with respiratory distress occurred, with similar presentation requiring supportive treatment in intensive care. Recent evaluation at 4.5 years revealed insensitivity to pain, significant motor, and speech delay (not yet sitting and no speech). She weighed 14 kg (-2.0 SD), length 96 cm (-2.6 SD), and OFC measured 49 cm (-0.67 SD). Craniofacial features were similar to her affected sibling (Figure S1f-h). She had lower limb muscle atrophy, central and peripheral hypotonia with lower limb spasticity, lower limb reflexes were absent, and Babinski sign was negative bilaterally.

3 | GENETIC ANALYSIS

Whole exome sequencing (WES) (Illumina NextSeq500 and Twist Human Core Exome Kit) was undertaken on DNA from both siblings, with informed consent (Palestinian Health Research Council [PHRC/HC/518/19]). The WES bioinformatic pipeline, filtering, and analysis were undertaken as described previously (Rawlins et al., 2022), assuming that a homozygous founder variant was responsible, although also considering other genetic mechanisms. This identified a single shared candidate homozygous variant (Chr14:g.102425085G>A; NM_014844.5:c.745G>A, p.(Gly249Arg) [hg38]) in exon 6/20 of *TECPR2* within the C-terminus WD40 domain (Figure 1c), located within the largest genomic region (5.73 Mb) of shared homozygosity. The variant segregated as appropriate for an autosomal recessive disorder (Figure 1a), is absent from population databases (gnomAD, v2.1.1/v3.1.2 accessed on September 1, 2023) and a database of >8000 regional exome/genomes, results in substitution of a highly conserved residue (Figure 1b), and is predicted deleterious by multiple *in silico* prediction tools (REVEL 0.574, CADD 25.4; Table S1).

To further investigate the pathogenicity of the NM_014844.5:c.745G>A, p.(Gly249Arg) variant, we generated a *TECPR2* protein model using AlphaFold, alongside other previously published *TECPR2* missense variants (Figure S2). This did not identify any clustering of variants that are distributed across the proteins three β -propeller folds, with no discernible impact on protein folding and function for any of the *TECPR2* variants. This led us to further reassess the pathogenicity of any previously published *TECPR2* missense variants according to American College of Medical Genetics (ACMG)/Association for Molecular Pathology (AMP) guidelines (Table S1), all of which are classified as variants of uncertain significance (VUS) except one previously reported variant NM_014844.5:c.2050C>G, p.(Leu684Val) that has been reclassified as benign, with a high allele frequency in gnomAD (Table S1) (Covone et al., 2016).

4 | DISCUSSION

A current challenge in interpreting the clinical relevance of genetic variants present in individuals from Palestinian populations stems from the extremely poor representation of this group in population databases including gnomAD (v3.1.2), in which only 158 out of 76,156 genomes are of Middle Eastern origin. The absence of a variant in publicly available population databases is thus currently of limited value for indicating pathogenicity in ethnically diverse populations, underscoring the importance of continued efforts to diversify the genomic evidence base (Koch, 2020). While several population-specific databases including GenomeAsia (<https://browser.genomeasia100k.org/>) (Wall et al., 2019) and the Greater Middle East (GME) Variome Project (<http://igm.ucsd.edu/gme/>) (Scott et al., 2016; Vatsyayan et al., 2021) are ongoing to specifically address this genomic data disparity, all have no or very limited numbers of Palestinian exomes and genomes. This issue is further compounded by the relatively high number of homozygous missense variants typically

identified in such genetically isolated communities, in which inter-community marriage patterns tend to be common (Darr et al., 2016).

Here, we identified the likely cause of early-onset developmental delay complicated by recurrent episodes of acute encephalopathy, central hypoventilation and multisystem injury in two Palestinian siblings as a biallelic novel p.(Gly249Arg) *TECPR2* missense variant. While this is classified as a VUS using current guidelines (Table S1), PM2 criteria should be applied with caution given the poor representation in population databases. Additionally this variant impacts the N-terminus WD40 domain architecture of the molecule where two other *TECPR2* missense VUSs have previously been reported (Neuser et al., 2021) (Figure 1c), although further protein modeling studies have not provided clear evidence to support pathogenicity. *TECPR2* is an interactor of the autophagy-related protein 8 (ATG8) family of proteins implicated in the lysosomal degradation autophagy pathway (Fraiberg et al., 2021; Stadel et al., 2015). Consistent with this, studying brain sections of *tecp2*^{-/-} mice, which phenotypically overlap with the human condition, identified the accumulation of autophagosomes suggestive of a role of *TECPR2* in lysosomal targeting (Tamim-Yecheskel et al., 2021). Previous studies indicate that the C-terminal *TECPR2* lysosome interacting domains are important for targeting to autophagosomes (Fraiberg et al., 2021; Stadel et al., 2015), mediated by the N-terminal WD40 domains important for protein stabilization and interaction with the autophagosomal membrane (Fraiberg et al., 2021; Stadel et al., 2015; Tamim-Yecheskel et al., 2021) (Figure 1c).

Interestingly Hahn et al. (2015) described a neuroaxonal dystrophy associated with a homozygous pathogenic missense *Tecpr2* variant (c.4135C>T; p.(Arg1379Trp)) in Spanish water dogs, with a phenotype overlapping that seen in patients, and provides support for missense variant pathogenicity. Neuser et al. (2021) proposed that missense variants cluster within the N-terminus and C-terminus domains, regions with higher levels of constraint for missense variation and high CADD scores. Subsequently, a case report by Guan et al. (2022) identified a Chinese patient with features consistent with *TECPR2*-HSAN and compound heterozygous *TECPR2* missense VUSs, one (NM_014844.5:c.1729C>T, p.(His577Tyr)) located within the central domain of the protein (Figure 1c). This suggests that the central domain may also have an important functional role, although our protein modeling studies did not identify clustering or predict any significant structural impact on the protein. Similar to the Palestinian variant presented here, poor representation of the Chinese population within publicly available genomic reference databases renders missense variant interpretation challenging. The *TECPR2* p.(His577Tyr) variant is listed in gnomAD v3.1.2 at an allele frequency of 0.000046, whereas within the HUABIAO Han Chinese database, the allele frequency is higher at 0.00141, suggesting it may represent a founder variant in this region. Further, there are 226 missense variants currently listed in ClinVar (<https://www.ncbi.nlm.nih.gov/clinvar/>) as VUS, with no likely pathogenic/pathogenic variants. To date, no missense *TECPR2* variant has been found *in trans* with a confirmed pathogenic loss-of-function variant that could support pathogenicity of *TECPR2* missense variants and an effective functional assay(s) to assist

in interpretation of *TECPR2* missense variant pathogenicity are urgently needed.

Although the phenotype of the two siblings presented here and that of individuals previously reported with missense variants are highly consistent with that described in patients with pathogenic *TECPR2* loss-of-function variants, there are no highly specific features which precludes use of the PP4 criterion according to ACMG/AMP guidelines. Oz-Levi et al. (2013) described three unrelated Jewish Bakharian families with a novel form of HSP associated with a homozygous *TECPR2* founder variant NM_014844.5:c.3416del, p.(Leu1139Argfs*75). Subsequent further families have been identified with biallelic pathogenic *TECPR2* variants including a recent large cohort of 24 families (Neuser et al., 2021) and the condition has more recently been classified as a form of hereditary sensory autonomic neuropathy; *TECPR2*-HSAN (Heimer et al., 2022). As with previous descriptions, the siblings described here displayed transient episodes triggered by intercurrent infection of acute encephalopathy, autonomic dysregulation with respiratory difficulties requiring intubation and mechanical ventilation, generalized seizures, worsening hypotonia, unstable body temperature, and blood pressure dysregulation. In both affected individuals, this was associated with severe electrolyte imbalance with hypernatremic dehydration, hyperglycemia, hypocalcemia, hypokalemia, and raised liver enzymes, creatinine and CK indicating acute liver, kidney and muscle injury. In Individual IV:2, an acute encephalopathic episode at 5.5 years led to a rapidly progressive metabolic acidosis with multiorgan failure resulting in death that was not attributable to sepsis. In Individual IV:3, a severe transient myopathy was associated with an acute encephalopathic episode with dramatically elevated CK, CK-MB, and LDH. Intermittent elevation of transaminases has been identified in two previously reported patients, Individual II-2, Family B in Oz-Levi et al. (2013) associated with acute encephalopathic episodes and Individual P1 in Neuser et al. (2021) associated with acidosis, hyperglycemia, and raised CK, with no recorded episodes of acute encephalopathy. No previously identified individuals have been reported to have transient myopathy, although a number have increased hypotonia during acute events. Interestingly, all metabolic investigations of affected individuals reported here and those previously published identified no abnormalities (Neuser et al., 2021), although the possibility of a second diagnosis of an inherited metabolic disorder cannot be completely excluded given the family structure, all other shared homozygous variants were excluded.

Although death in early childhood has been reported in two other individuals with *TECPR2*-HSAN at the ages of 5.5 and 6 years, this was attributed to sepsis resulting from severe aspiration pneumonia (Heimer et al., 2016; Oz-Levi et al., 2013) or nocturnal central apnea (Heimer et al., 2022); Individual IV:2 is the first reported individual with *TECPR2*-HSAN to die from an episode of acute encephalopathy and autonomic dysregulation leading to multi-organ failure. Both siblings IV:2 and IV:3 have severe sensorineural hearing loss, a variable feature described in six previously identified individuals (Heimer et al., 2016; Neuser et al., 2021), although there does not appear to be any correlation with the severity of the condition. Additionally,

both have significant gastrointestinal manifestations; individual IV:2 has chronic constipation and individual IV:3 has severe dysphagia and gastroesophageal reflux leading to recurrent aspiration pneumonia requiring gastrostomy insertion. This is a common presentation with nine reported individuals requiring gastrostomy insertion for severe gastrointestinal manifestations (Heimer et al., 2016; Neuser et al., 2021). MRI neuroimaging is consistent with previous reports, including thinning of the corpus callosum, ventriculomegaly, and markedly reduced cerebral volume (Neuser et al., 2021). Facial features of these siblings are consistent with those previously noted in individuals with *TECPR2*-HSAN, including a short neck, rounded face, and prominent nose (Figure S1), although a recognizable facial gestalt is not apparent in this condition.

Our study identifies two Palestinian siblings presenting with acute encephalopathy and severe life-threatening multi-organ dysfunction/failure manifesting with liver injury and kidney failure. Transient myopathy has not previously been reported in association with *TECPR2*-HSAN; however, we would propose that this is likely to be an uncommon component of this condition. Importantly, this work highlights the challenges in interpretation of rare genomic variants in populations underrepresented in publicly accessible genomic databases and the ensuing healthcare inequalities for families affected by rare genetic disorders.

AUTHOR CONTRIBUTIONS

Reham Khalaf-Nazzal: Conceptualization; investigation; funding acquisition; supervision; writing—original draft; writing—review and editing. **Imad Dweikat:** Investigation, writing—review and editing. **Nishanka Ubeyratna:** Data curation, writing—review and editing. **James Fasham:** Data curation, writing—review and editing. **Maysa Alawneh:** Investigation, writing—review and editing. **Joseph Leslie:** Investigation, writing—review and editing. **Mosab Maree:** Investigation, writing—review and editing. **Adam Gunning:** Investigation, writing—review and editing. **Deyala Z. Zayed:** Investigation, writing—review and editing. **Nikol Voutsina:** Investigation, writing—original draft, writing—review and editing. **Lucy McGavin:** Investigation, writing—review and editing. **Reem Sawafta:** Investigation, writing—review and editing. **Martina Owens:** Investigation, writing—review and editing. **Wisam Baker:** Investigation, writing—review and editing. **Peter Turnpenny:** Conceptualization, supervision, writing—review and editing. **Fida' Al-Hijawi:** Conceptualization, investigation, writing—review and editing. **Emma L. Baple:** Conceptualization, investigation, funding acquisition, supervision, writing—original draft, writing—review and editing. **Andrew H. Crosby:** Conceptualization, investigation, funding acquisition, supervision, writing—original draft, writing—review and editing. **Lettie E. Rawlins:** Conceptualization, investigation, supervision, writing—original draft, writing—review and editing.

ACKNOWLEDGMENTS

The authors are grateful to the family and the wider community for their participation and support of this study. We thank Ms. Kefaya Haj-Ahmad, field coordinator and patient liaison person in the “Stories

of Hope, Stories from Palestine” community genomics research project for her continued logistic support. The study was funded by the Unity and Diversity in Nature and Society Project, European Union (ENI/2019/412-148) to R.K.N., Medical Research Council (MRC) Proximity to Discovery and Confidence in Concept grants (MC-PC-18047, MC_PC_15054) to E.L.B. and A.H.C. and G1002279 (A.H.C.) and Medical Research Foundation Changing Policy and Practice award MRF-145-0006-DG-BAPL-C0788 to E.L.B. and A.H.C. This study was supported by the National Institute for Health and Care Research Exeter Biomedical Research Centre. The views expressed are those of the authors and not necessarily those of the NIHR or the Department of Health and Social Care. For the purpose of open access, the author has applied a ‘Creative Commons Attribution (CC BY) licence’ to any Author Accepted Manuscript version arising from this submission.

CONFLICT OF INTEREST STATEMENT

The authors declare no conflicts of interest.

DATA AVAILABILITY STATEMENT

The data that support the findings of this study are available from the corresponding author upon reasonable request.

ORCID

James Fasham  <https://orcid.org/0000-0002-7614-9202>

Emma L. Baple  <https://orcid.org/0000-0002-6637-3411>

Andrew H. Crosby  <https://orcid.org/0000-0003-3667-9054>

Lettie E. Rawlins  <https://orcid.org/0000-0002-6764-253X>

REFERENCES

- Covone, A. E., Fiorillo, C., Acquaviva, M., Trucco, F., Morana, G., Ravazzolo, R., & Minetti, C. (2016). WES in a family trio suggests involvement of TECPR2 in a complex form of progressive motor neuron disease. *Clinical Genetics*, 90(2), 182–185. <https://doi.org/10.1111/cge.12730>
- Darr, A., Small, N., Ahmad, W. I. U., Atkin, K., Corry, P., & Modell, B. (2016). Addressing key issues in the consanguinity-related risk of autosomal recessive disorders in consanguineous communities: Lessons from a qualitative study of British Pakistanis. *Journal of Community Genetics*, 7(1), 65–79. <https://doi.org/10.1007/s12687-015-0252-2>
- Fraiberg, M., Tamim-Yecheskel, B. C., Kokabi, K., Subic, N., Heimer, G., Eck, F., Nalbach, K., Behrends, C., Ben-Zeev, B., Shatz, O., & Elazar, Z. (2021). Lysosomal targeting of autophagosomes by the TECPR domain of TECPR2. *Autophagy*, 17(10), 3096–3108. <https://doi.org/10.1080/15548627.2020.1852727>
- Guan, Y., Lu, H., Zuo, W., Wang, X., Wang, S., Wang, X., Liu, F., Jia, K., Gao, R., Wu, H., Shi, Z., & Ji, Y. (2022). Novel detection of mutation in the TECPR2 gene in a Chinese hereditary spastic paraplegia 49 patient: A case report. *BMC Neurology*, 22(1), 47. <https://doi.org/10.1186/s12883-022-02572-x>
- Hahn, K., Rohdin, C., Jagannathan, V., Wohlsein, P., Baumgärtner, W., Seehusen, F., Spitzbarth, I., Grandon, R., Drögemüller, C., & Jäderlund, K. H. (2015). TECPR2 associated neuroaxonal dystrophy in Spanish water dogs. *PLoS One*, 10(11), e0141824. <https://doi.org/10.1371/journal.pone.0141824>
- Heimer, G., Neuser, S., Ben-Zeev, B., & Ebrahimi-Fakhari, D. (2022). TECPR2-related hereditary sensory and autonomic neuropathy with intellectual disability. In M. P. Adam, D. B. Everman, & G. M. Mirzaa (Eds.), *GeneReviews® [Internet]*. University of Washington. <https://www.ncbi.nlm.nih.gov/books/NBK584409/>
- Heimer, G., Oz-Levi, D., Eyal, E., Edvardson, S., Nissenkorn, A., Ruzzo, E. K., Szeinberg, A., Maayan, C., Mai-Zahav, M., Efrati, O., Pras, E., Reznik-Wolf, H., Lancet, D., Goldstein, D. B., Anikster, Y., Shalev, S. A., Elpeleg, O., & Ben Zeev, B. (2016). TECPR2 mutations cause a new subtype of familial dysautonomia like hereditary sensory autonomic neuropathy with intellectual disability. *European Journal of Paediatric Neurology*, 20(1), 69–79. <https://doi.org/10.1016/j.ejpn.2015.10.003>
- Karczewski, K. J., Francioli, L. C., Tiao, G., Cummings, B. B., Alfoldi, J., Wang, Q., Collins, R. L., Laricchia, K. M., Ganna, A., Birnbaum, D. P., Gauthier, L. D., Brand, H., Solomonson, M., Watts, N. A., Rhodes, D., Singer-Berk, M., England, E. M., Seaby, E. G., Kosmicki, J. A., ... Daly, M. J. (2020). The mutational constraint spectrum quantified from variation in 141,456 humans. *Nature*, 581(7809), 434–443. <https://doi.org/10.1038/s41586-020-2308-7>
- Koch, L. (2020). Exploring human genomic diversity with gnomAD. *Nature Reviews Genetics*, 21(8), 448. <https://doi.org/10.1038/s41576-020-0255-7>
- Neuser, S., Brechmann, B., Heimer, G., Brösse, I., Schubert, S., O’Grady, L., Zech, M., Srivastava, S., Sweetser, D. A., Dincer, Y., Mall, V., Winkelmann, J., Behrends, C., Darras, B. T., Graham, R. J., Jayakar, P., Byrne, B., Bar-Aluma, B. E., Haberman, Y., ... Ebrahimi-Fakhari, D. (2021). Clinical, neuroimaging, and molecular spectrum of TECPR2-associated hereditary sensory and autonomic neuropathy with intellectual disability. *Human Mutation*, 42(6), 762–776. <https://doi.org/10.1002/humu.24206>
- Oz-Levi, D., Gelman, A., Elazar, Z., & Lancet, D. (2013). TECPR2: A new autophagy link for neurodegeneration. *Autophagy*, 9(5), 801–802. <https://doi.org/10.4161/auto.23961>
- Popejoy, A. B., Ritter, D. I., Crooks, K., Currey, E., Fullerton, S. M., Hindorf, L. A., Koenig, B., Ramos, E. M., Sorokin, E. P., Wand, H., Wright, M. W., Zou, J., Gignoux, C. R., Bonham, V. L., Plon, S. E., & Bustamante, C. D. (2018). The clinical imperative for inclusivity: Race, ethnicity, and ancestry (REA) in genomics. *Human Mutation*, 39(11), 1713–1720. <https://doi.org/10.1002/humu.23644>
- Ramsey, K., Belnap, N., Bonfitto, A., Jepsen, W., Naymik, M., Sanchez-Castillo, M., Craig, D. W., Szelinger, S., Huentelman, M. J., Narayanan, V., & Rangasamy, S. (2022). Progressive cerebellar atrophy caused by heterozygous TECPR2 mutations. *Molecular Genetics and Genomic Medicine*, 10(2), e1857. <https://doi.org/10.1002/mgg3.1857>
- Rawlins, L. E., Almousa, H., Khan, S., Collins, S. C., Milev, M. P., Leslie, J., Saint-Dic, D., Khan, V., Hincapie, A. M., Day, J. O., McGavin, L., Rowley, C., Harlalka, G. V., Vancollie, V. E., Ahmad, W., Lelliott, C. J., Gul, A., Yalcin, B., Crosby, A. H., ... Baple, E. L. (2022). Biallelic variants in TRAPPC10 cause a microcephalic TRAPPopathy disorder in humans and mice. *PLoS Genetics*, 18(3), e1010114. <https://doi.org/10.1371/journal.pgen.1010114>
- Scott, E. M., Halees, A., Itan, Y., Spencer, E. G., He, Y., Azab, M. A., Gabriel, S. B., Belkadi, A., Boisson, B., Abel, L., Clark, A. G., Rahim, S. A., Abdel-Hadi, S., Abdel-Salam, G., Abdel-Salam, E., Abdou, M., Abhytanka, A., Adimi, P., Ahmad, J., ... Zhang, S. Y. (2016). Characterization of greater middle eastern genetic variation for enhanced disease gene discovery. *Nature Genetics*, 48(9), 1071–1076. <https://doi.org/10.1038/ng.3592>
- Sirugo, G., Williams, S. M., & Tishkoff, S. A. (2019). The missing diversity in human genetic studies. *Cell*, 177(1), 26–31. <https://doi.org/10.1016/j.cell.2019.02.048>
- Stadel, D., Millarte, V., Tillmann, K. D., Huber, J., Tamin-Yecheskel, B. C., Akutsu, M., Demishtein, A., Ben-Zeev, B., Anikster, Y., Perez, F., Dötsch, V., Elazar, Z., Rogov, V., Farhan, H., & Behrends, C. (2015). TECPR2 cooperates with LC3C to regulate COPII-dependent ER export. *Molecular Cell*, 60(1), 89–104. <https://doi.org/10.1016/j.molcel.2015.09.010>
- Tamim-Yecheskel, B. C., Fraiberg, M., Kokabi, K., Freud, S., Shatz, O., Marvaldi, L., Subic, N., Brenner, O., Tsoory, M., Eilam-Altstadter, R., Biton, I., Savidor, A., DeZorella, N., Heimer, G., Behrends, C., Ben-

- Zeev, B., & Elazar, Z. (2021). A *tecp2* knockout mouse exhibits age-dependent neuroaxonal dystrophy associated with autophagosome accumulation. *Autophagy*, 17(10), 3082–3095. <https://doi.org/10.1080/15548627.2020.1852724>
- Vatsyayan, A., Sharma, P., Gupta, S., Sandhu, S., Venu, S. L., Sharma, V., Badaoui, B., Azedine, K., Youssef, S., Rajab, A., Fayez, A., Madinur, S., Ranawat, A., Pandhare, K., Ramachandran, S., Sivasubbu, S., & Scaria, V. (2021). DALIA—A comprehensive resource of disease alleles in Arab population. *PLoS ONE*, 16(1), e0244567. <https://doi.org/10.1371/journal.pone.0244567>
- Wall, J. D., Stawiski, E. W., Ratan, A., Kim, H. L., Kim, C., Gupta, R., Suryamohan, K., Gusareva, E. S., Purbojati, R. W., Bhangale, T., Stepanov, V., Kharkov, V., Schröder, M. S., Ramprasad, V., Tom, J., Durinck, S., Bei, Q., Li, J., Guillory, J., ... Peterson, A. S. (2019). The GenomeAsia 100K project enables genetic discoveries across Asia. *Nature*, 576(7785), 106–111. <https://doi.org/10.1038/s41586-019-1793-z>

SUPPORTING INFORMATION

Additional supporting information can be found online in the Supporting Information section at the end of this article.

How to cite this article: Khalaf-Nazzal, R., Dweikat, I., Ubeyratna, N., Fasham, J., Alawneh, M., Leslie, J., Maree, M., Gunning, A., Zayed, D. Z., Voutsina, N., McGavin, L., Sawafta, R., Owens, M., Baker, W., Turnpenny, P., Al-Hijawi, F., Baple, E. L., Crosby, A. H., & Rawlins, L. E. (2024). *TECPR2*-related hereditary sensory and autonomic neuropathy in two siblings from Palestine. *American Journal of Medical Genetics Part A*, e63579. <https://doi.org/10.1002/ajmg.a.63579>